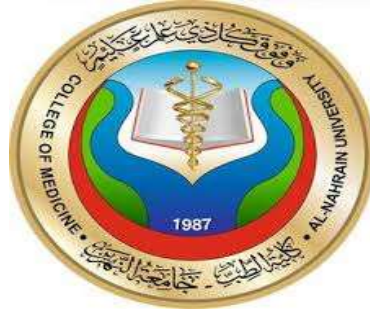



ALNAHRAIN UNIVERSITY
COLLEGE OF MEDICINE
DEPARTMENT OF MEDICINE

REVERSIBLE ELECTROCARDIOGRAPHIC CHANGES
IN ACUTE SEVERE ASTHMA IN THE EMERGENCY
DEPARTMENT

Done by:
Sabah Hussain Hantosh

Supervised by:
Dr. Hashim M. Hashim

Professor of medicine

2018-2019

DEDICATION

To my parents for their support and encouragement throughout the studying years and to every person that taught me a letter in my life .

ACKNOWLEDGMENT

I would like to express my deep gratitude and appreciation to
Dr. Hashim M. Hashim
For his kind supervision, direction and constant support and
encouragement.

List of content :

Item	PAGE
ABSTRACT	5
INTRODUCTION	6
AIM OF STUDY	9
PATIENT AND METHOD	10
RESULTS	13
DISCUSSION	17
CONCLUSION	19
REFERENCES	20

Abstract:

Aim of the study :

The aim of our study is to determine the reversible ECG changes in acute severe asthma patients .

Design:

Prospective .

Patients and method :

A cross-sectional study included a sample of 30 patients 15 male and 15 female , Age between 14 and 84 years , suffering from acute severe asthma in AL- Imamein AL-Kadhemein medical city in the emergency department where chosen randomly in the period between 24th of October 2018 and 15th of January 2019 .

Results:

The ECG was normal in 4 patients (13%) , the most common ECG change was sinus tachycardia in 14 patients (47%) , abnormaly vertical p wave axis in 7 patients (23%). right ventricular hypertrophy in 4 patients (13%) P- pulmonale in one patient (3%) .

Conclusion:

This study determine that all ECG changes except for those suggesting myocardial ischemia are in fact explicable on purely anatomical grounds. Over distension of the lungs, in addition to altering the electrical axis, may alter the position of the heart to such an extent that the anterior chest leads for instance, no longer reflect the activity of that part of the heart which they would normally individually represent.

REVERSIBLE ELECTROCARDIOGRAPHIC CHANGES IN ACUTE SEVERE ASTHMA

INTRODUCTION

Asthma is a common long-term inflammatory disease of the airways of the lungs.^[1] It is characterized by variable and recurring symptoms, reversible airflow obstruction, and bronchospasm.^[2] Symptoms include episodes of wheezing, coughing, chest tightness, and shortness of breath.^[4]

Acute severe asthma is an acute exacerbation of asthma that does not respond to standard treatments of bronchodilators (inhalers) and corticosteroids.^[3] These episodes may occur a few times a day or a few times per week, Depending on the person they may become worse at night or with exercise.^[3]

An exacerbation (attack) of asthma is experienced as a worsening of asthma symptoms and increase in airway inflammation with breathlessness and cough (often worse at night). In acute severe asthma, breathlessness may be so severe that it is impossible to speak more than a few words (inability to complete sentences).^[5]

Most attacks are characterised by a gradual deterioration over several hours to days, but some appear to occur little or no warning: so called brittle asthma^[5]

Hypoxia is an important finding in the evaluation of the severity of asthma attacks, in life-threatening asthma the oxygen saturation is usually below (92%) and cyanosis may be present in those patients, so it is important to know the oxygen saturation of any patient presenting with acute exacerbation of asthma.^[6]

Table(1) Immediate assessment of acute severe asthma :^[6]

Near-fatal	High <u>PaCO₂</u> , or requiring mechanical ventilation, or both	
Life-threatening (any one of)	Clinical signs	Measurements
	Altered <u>level of consciousness</u>	<u>Peak flow</u> < 33%
	Exhaustion	<u>Oxygen saturation</u> < 92%
	<u>Arrhythmia</u>	<u>PaO₂</u> < 8 kPa
	Low <u>blood pressure</u>	"Normal" or raised PaCO ₂
	<u>Cyanosis</u>	
	Silent chest	
	Poor respiratory effort	
Acute severe (any one of)	Peak flow 33–50%	
	Respiratory rate ≥ 25 breaths per minute	
	Heart rate ≥ 110 beats per minute	
	Unable to complete sentences in one breath	

ECG changes in acute severe asthma :

Reversible abnormalities in the electrocardiogram are well recognised in patients with acute attacks of bronchial asthma. The most common change is sinus tachycardia .

Previously reported changes have included right axis deviation, prominent P waves suggesting right atrial enlargement, inversion of T waves, right bundle-branch block, and abnormalities of the ST segment ^[7] .

. All ECG changes resolved after clinical improvement ^[7]

.

AIM OF STUDY

The aim of our study is to determine the reversible ECG changes
in acute severe asthma patients .

Patients and methods

Patients:

A cross-sectional study included a sample of (30) patients was conducted in AL imamein Alkadhomein medical city in the emergency department were chosen randomly .

Data was collected under the following headings : age , sex , serum potassium , pulse rate , peak flow meter , oxygen saturation and ECG changes , from 30 case notes in the period between October.24.2018 to January.15.2019. they were divided into different age groups and also separated into male and female.

Age:

Sex:

Address:

Accupation:

Duration:

STABLE

unstable

ventolin use

serum potassium level (mg/dl):

ECG changes:

pulse rate (bpm):

peak flow (%) :

oxygen saturation (%) :

These total 30 asthma patients comprised of 15 male and 15 female (male to female ratio 1:1) there ages were ranging from 14y. to 84y.

there were 5 patients between 14y. to 29y. and 12 patients from 30y. to 49 and 13 patients from 50y. to 84 y.

method:

A standard 12-lead ECG was performed. The ECG was examined for abnormalities of rhythm and of P- or QRS-wave axis. Right atrial enlargement was judged to be present if the height of the P wave in standard leads II and III exceeded 2.5 mm (P pulmonale). Right ventricular hypertrophy was regarded as being present if there was right axis deviation to beyond $+110^\circ$, the height of the R wave in V1 exceeded 5 mm, and the ratio of R-wave amplitude to S-wave amplitude in V6 exceeded unity. The P-wave axis was abnormally vertical, ie, more than 90° , if the P-wave in standard leads II and III was taller than in standard lead I and the P wave was negative in lead aVL. ^[8]

Serum potassium was performed in the laboratory of the emergency department .

Pulse rate was measured for patients on admission to the emergency department .

Oxygen saturation measured by pulse oximetry on admission.

Peak flow measured in percentage by peak flow meter using the following formula :

Average daily variability= $100 * (\text{highest PEF} - \text{lowest PEF}) / \text{highest PEF}$.

Results :

The ECG was normal in 4 patients (13%) , the most common ECG change was sinus tachycardia in 14 patients (47%) , abnormally vertical p wave axis in 7 patients (23%). right ventricular hypertrophy in 4 patients (13%) P- pulmonale in one patient (3%).the mean age of patients with tachycardia was 46 years, For vertical p-wave axis was 50 years, for RVH it was 68 years. For p-pulmonale it was 46 y. mean age for normal rythem pateints was 21 y.

Case	total	Percent	Male number	Male percent	Female number	Female percent
Normal sinus rythem	4	13%	2	50%	2	50%
Sinus tachycardia	14	47%	7	50%	7	50%
RVH.	4	13%	3	75%	1	25%
Vertical p wave	7	23%	4	57%	3	43%
p-pulmonale	1	3%	1	100%	0	0%

Table (2): determine the number & percent of patients with ECG changes :

The average pulse rate in patients with normal sinus rythem was 81.45 bpm , in sinus tachycardia was 118.28bpm , in vertical p-wave the pulse rate was 110 bpm. In RVH. It was 128.75 bpm, In p- pulmonale 120 bpm.

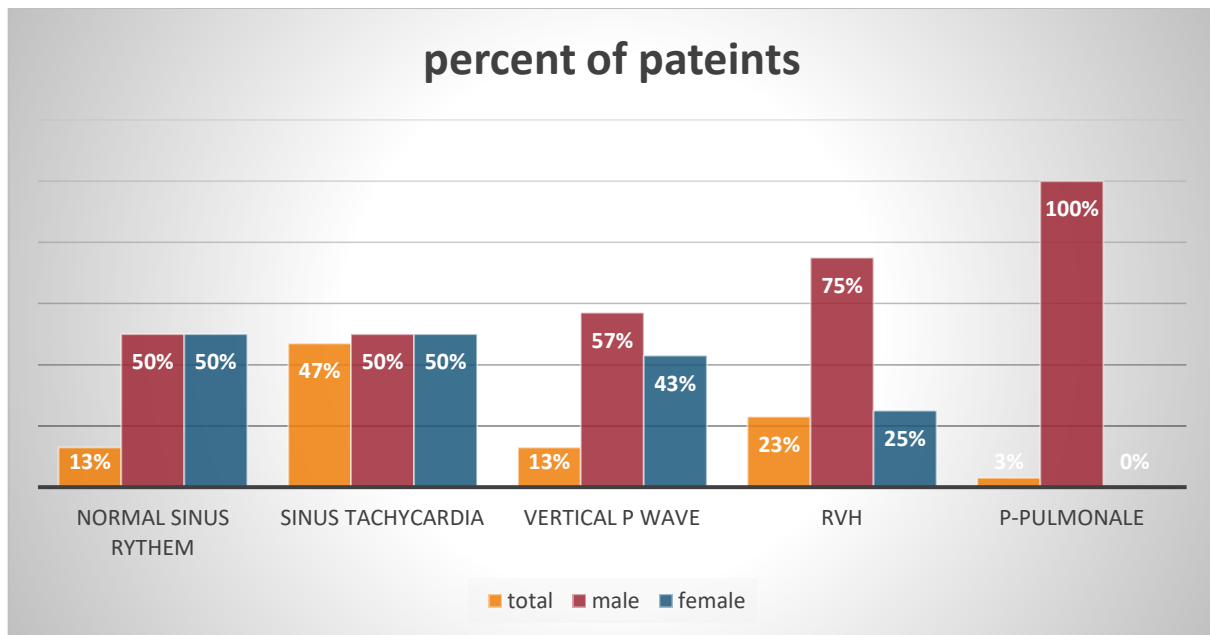
According to peak expiratory flow rate it was (53%) in patients with normal sinus rythem , (36%) in patients with sinus tachycardia , (30%) in patients with RVH. and (35%) in patients with vertical p – wave and 30%in p-pulmonale .

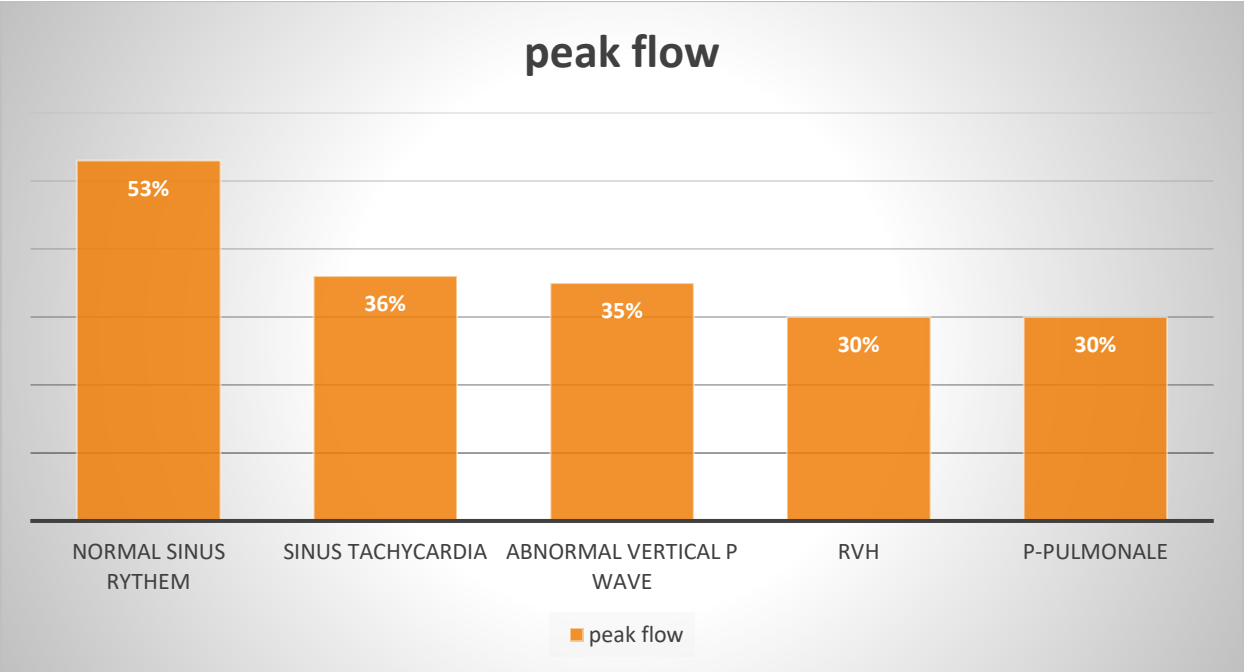
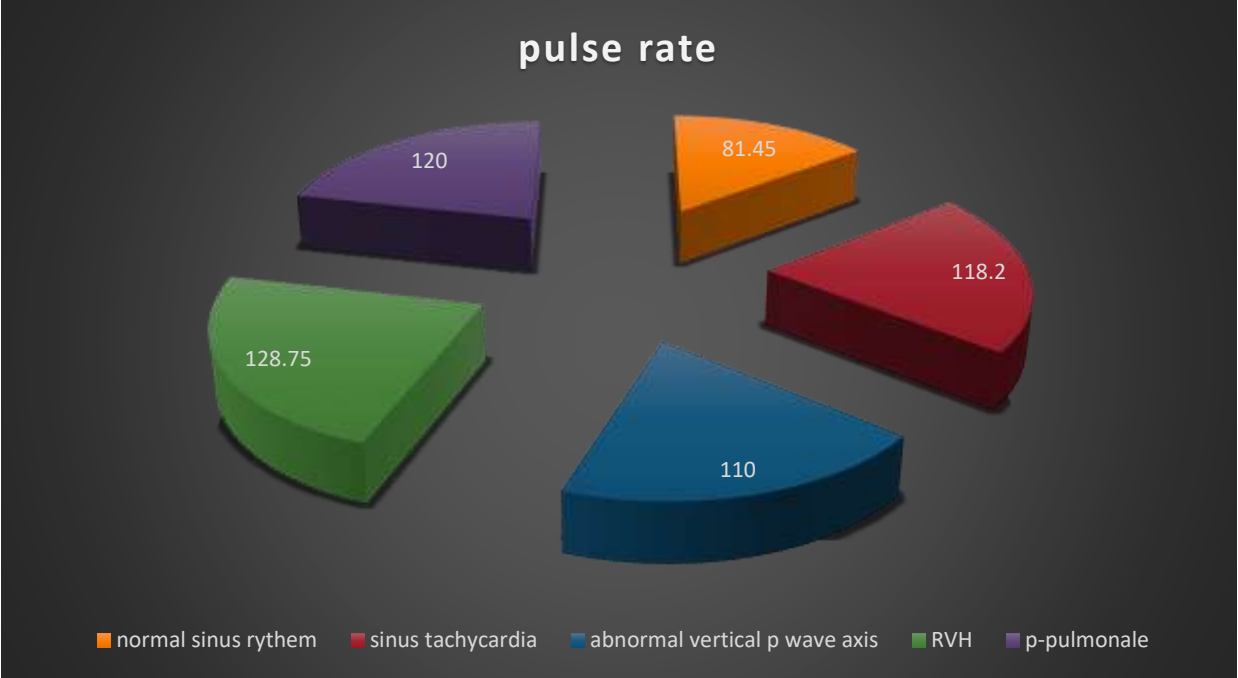
The oxygen saturation was 93% in normal sinus rythem , 91% in sinus tachycardia , 87% in RVH. , 90% in abnormally vertical p wave axis and (87%) in p-pulmonale . The serum potassium level was 4.018 mg/dl in patients with normal sinus rythem , 3.5 mg/dl in patients with sinus tachycardia , 3.4 mg/dl in patients

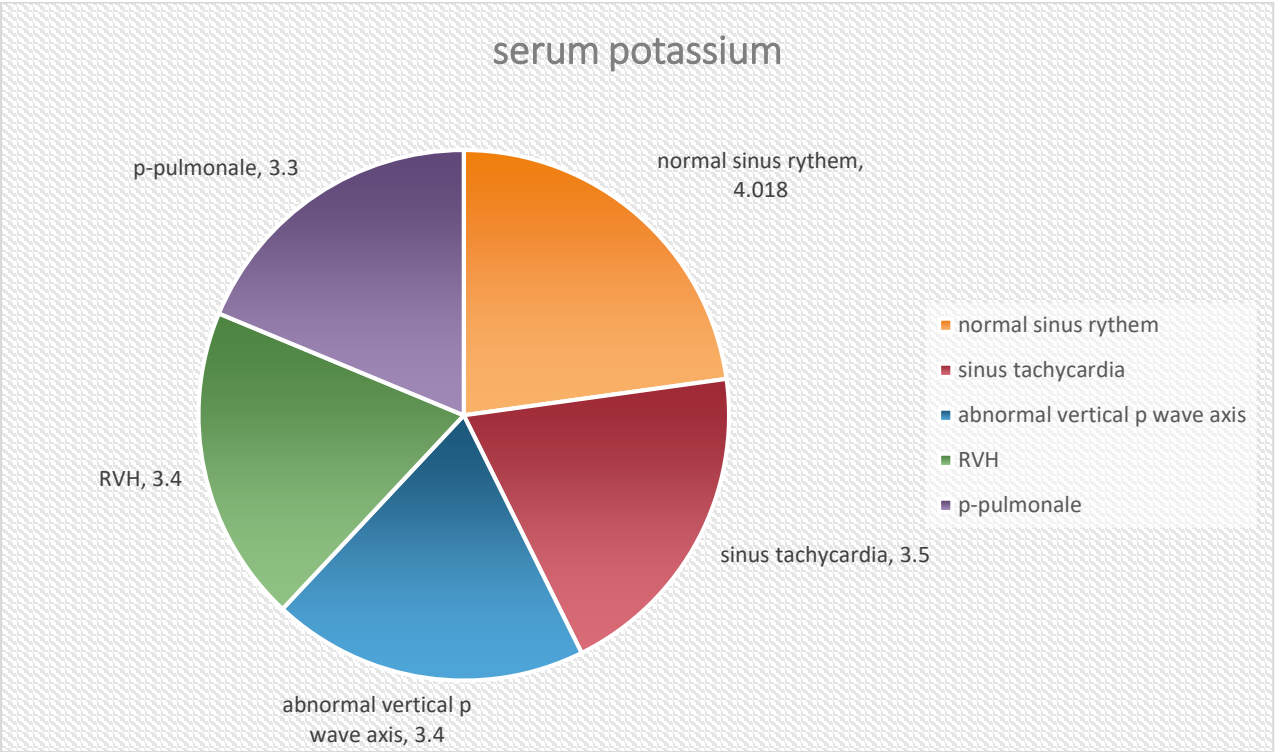
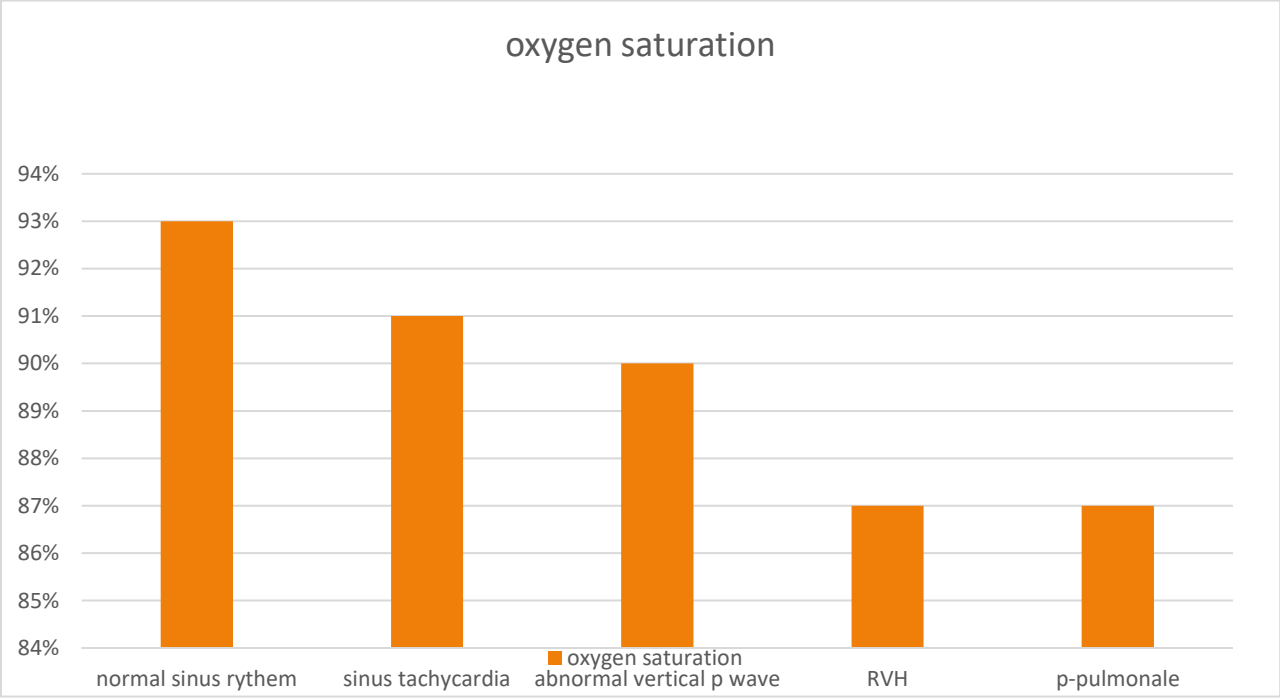
with RVH and 3.4 mg/dl in vertical p – wave patients and (3.3) in p-pulmonale patient .

Case	Pulse rate	Peak flow	Oxygen saturation	s. potassium mg/dl
Normal sinus rythem	81.4545	53%	93%	4.018
sinus tachycardia	118.28	36%	91%	3.5
RVH	128.75	30%	87%	3.4
Vertical p-wave axis	110	35%	90%	3.4
p-pulmonale	120	30%	87%	3.3

Table (3): show (pulse rate, peak flow, o₂ saturation, s.k) in acute severe sthma :







DISCUSSION:

In the present study that include 30 patients collected randomly in the emergency department of AL-imamein alkadhemein medical city the commonest ECG changes was sinus tachycardia in 14 patients (47%) then the abnormally vertical p-wave axis in 7 patients (23%), RVH in 4 patients (13%) and p-pulmonale in one patient (3%). Previous study on 63 patients document that The most consistent change was an abnormally vertical P-wave axis in 48 of the patients (78%). In those patients in whom further ECGs were performed once clinical improvement had been obtained, the P-wave axis had returned to normal, usually within three to four days, No rhythm disturbance was noted although a sinus tachycardia in excess of 100 per minute was present.^[9] RVH. in the present study was 4 patients (13%) while in previous study Right ventricular enlargement was present in only one patient.^[9] so the findings are similar to the findings of the present study but the differences in the number of patients because the total number of patients in the present study was less than in the previous one. in the present study p-pulmonale suggesting right atrial enlargement was only in one patient (3%), confirming the findings of previous study which was 6 out of 76 patients with p-pulmonale.^[10] and in another study it was 8 of 18 patients with p-pulmonale^[7]. in the previous study there was an abnormality in T-wave and ST segments it was the most unexpected abnormality in the ECG of the previous series^[9] and not found in the present study these changes suggesting myocardial ischemia as confirmed by previous reports.^[7] another study concluded that the appearances of abnormality in T-wave and ST-segment could be due to

autonomic nervous system activity or to adrenergic stimulation either therapeutically or by endogenous catecholamine release which might result in asynchronous repolarisation on the myocardium.

Hyperventilation and endogenous or therapeutic sympathomimetic stimulation could certainly explain the appearances of ischaemia in the first few hours of an attack of asthma. ^[11]

The inconsistency between the present series and previous reports was the absence from the present series of such changes as T-wave and ST segment abnormality . It could be argued that delays in recording the ECG could lead to these abnormalities being missed. This is a theoretical weakness of retrospective studies such as the present one. some ECG changes may disappear within hours. However, any delay in recording the ECG was unlikely to have made any material difference to the findings in the present study as some gross abnormalities did in fact persist for several days. The invariable persistence of sinus tachycardia suggests further that the heart was in some way still being influenced by the severe airway obstruction. ^[10]

Conclusion:

Finally, it is possible that all ECG changes except for those suggesting myocardial ischemia are in fact explicable on purely anatomical grounds. Over distension of the lungs, in addition to altering the electrical axis, may alter the position of the heart to such an extent that the anterior chest leads for instance, no longer reflect the activity of that part of the heart which they would normally individually represent. Also the study confirm that the ECG , peak flow meter and o₂ saturation are important parameters in the evaluation of severity of asthma attack and in the proper management of such cases .

References :

- 1- "Asthma Fact sheet №307". WHO. November 2013.
Archived from the original on June 29, 2011. Retrieved 3 March 2016
- 2- National Asthma Education and Prevention Program (2007). "Expert Panel Report 3: Guidelines for the Diagnosis and Management of Asthma" (PDF). National Heart Lung and Blood Institute.
- 3- Shah, R; Saltoun, CA (May–Jun 2012). "Chapter 14: Acute severe asthma (status asthmaticus)". *Allergy and Asthma Proceedings*. 33 Suppl 1 (3): S47-50. doi:10.2500/aap.2012.33.3547. PMID 22794687

- 4- "British Guideline on the Management of Asthma"(PDF). British Thoracic Society. 2012 [2008].
- 5- "SIGN 141 • British guideline on the management of asthma". *Clinical guideline: asthma*. London: *British Thoracic Society and Scottish Intercollegiate Guidelines Network (BTS/SIGN)*. October 2014. Retrieved 19 October 2014.
- 6- "British Guideline on the Management of Asthma"(PDF). British Thoracic Society. 2012 [2008].
- 7- - Da Costa, J. L. and Chia, B. L. (1974). The electrocardiographic changes in bronchial asthma and their relationship to the severity of airways obstruction. *Singapore Medical Journal*, 15, 101-105.

8- Estes, E. H., Jr. (1974). The ventricular electrocardiogram. In *The Heart*, edited by J. W. Hurst et al., 3rd edition, p. 306. McGraw-Hill, New York.

9- Siegler, D. (1977). *Thorax*, 32, 328-332. Reversible electrocardiographic changes in severe acute asthma.
<http://thorax.bmj.com/>

10- Rebuck, A. S. and Read, J. (1971). Assessment and management of severe asthma. *American Journal of Medicine*, 51, 788-798.

11- Biberman, L., Sarma, R. N., and Surawicz, B. (1971). T-wave abnormalities during hyperventilation and isoproterenol infusion. *American Heart Journal*, 81, 166-174.